

Iontophoresis with Aqueous solution of *Nirgundi* (*Vitex negundo*, Linn.) in the Management of *Pada Kantaka* (Plantar Fasciitis) - A Case Report

Case Report

Priyanka Patil^{1*}, Archana Kukade², Dushyant Patil³, Chaturbhuj Bhuyan⁴

1. Assistant Professor (Ph.D Scholar), 2. Associate Professor, 3. Assistant Professor, 4. Professor & Guide
Dr. D. Y. Patil College of Ayurved and Research centre, Dr. D. Y. Patil Vidyapeeth, Pimpri, Pune.

Abstract

Vata kantaka is recognized as a Vatvyadhi. Walking bare-foot on uneven terrains causes vitiation of Vata which inturn causes pain which is specifically located at the heel of the foot. Vitiating Vata gets localized in Pada and it produces its characteristic symptom which is pricking pain like a thorn especially in the morning for first few steps, so as to be called as Vata kantak. Acharya Yogratnakar stated Vata kantaka as Pada kantaka. A 35 years old female patient visited Shalya tantra OPD with complaints of Right heel pain and diagnosed as Plantar fasciitis. 6 sittings of Iontophoresis with Nirgundi Aqueous extract were given on alternate day for 15-20 min. Pain on VAS was 7 before treatment. After treatment the score reduced to 0. Nirgundi is well known for its analgesic, anti inflammatory, anti rheumatic property. Iontophoresis is a technique which improves the penetration of drug transdermally due to application of a low voltage current. So the iontophoresis with Nirgundi aqueous solution was found significantly effective in relieving symptoms of Pada kantaka i.e. Plantar fasciitis.

Key Words: *Pada Kantaka*, Plantar fasciitis, *Vatvyadhi*, Iontophoresis.

Introduction

Ayurveda postulates three main factors *Vata*, *Pitta*, and *Kapha* also known as *Tridosha*. Among *tridosha*, *Vata* is more vital because it controls *Pitta* and *Kapha* in order to accomplish various physiological functions(1). Owing to disrupting nature and challenging management *Vata Vyadhi* has been included in *Ashtamahagada*(2). *Pada kantaka* is also primarily recognized as *VataVyadhi*.

It has been elaborately stated by *Acharya Shushruta* as walking bare-foot on uneven terrains causes vitiation of *Vata* which inturn causes pain which is specifically located at the heel of the foot. During the process of pathogenesis when the vitiating *Vata* gets localized in *Pada*, It produces its characteristic symptom which is pricking pain like a thorn, so as to be called as *Vata kantak*(3). *Acharya Yogratnakar* has stated *Vata kantak* as *Pada kantaka*. *Acharya Sushruta* has contributed detailed account of exhaustive range of both surgical and para-surgical procedures in various ailments. He has also mentioned *Agnikarma* in severe painful conditions of *Twak*, *Mamsa*, *Sira*, *Snayu*, *Sandhi*, *Asthi* due to vitiating *Vata*(4).

Acharya Yogratnakar and *Acharya Chakradutta* has also indicated *Agnikarma* as therapeutic measure for *Pada kantak*(5).

Application of fatty material (*Sneha*), actual cauterization, massage, application of poultices and binding of ligatures should be the remedies where the aggravated *Vayu* would be found to have become involved in the *Snayu* (ligaments), joints and bones(6).

Acharya Sushruta has indicated *Agnikarma* for the treatment *vata prakopa* in *sandhi*, *asthi* and *snayu*(7). Thus *Agnikarma* can be efficiently employed as a therapeutic modality for *Pada kantaka*. The typical presentation of Plantar fasciitis is a history of intense sharp heel pain with the first couple of steps in the morning (8). It is the pain caused by degenerative irritation at the insertion of the plantar fascia on the medial process of the calcaneal tuberosity Initial conservative treatment of Plantar Fasciitis include a spectrum of modalities such as oral and local administration of NSAIDs and Stretching. When conservative treatment fails, treatment often progress to local infiltration of corticosteroids (Dexamethasone sodium phosphate 0.4%) and if no relief is

afforded then surgical release of plantar fascia is the option(9).

With advancement of technology, Iontophoresis with 0.4% Dexamethasone solution became progressively popular replacing steroid injection. In some studies Iontophoresis with herbal medicine is shown a very encouraging result. In China, one study by Zhou Feng-hui; Zhao Ming-jie and Zhao Hai-yan of First Affiliated Hospital of Medical College of Jinan University, Guangzhou, China) has reported 100% positive results by administration of traditional Chinese

* Corresponding Author:

Priyanka Patil

Assistant Professor (Ph.D Scholar),
Dr. D. Y. Patil College of Ayurved and Research
Centre, Dr. D. Y. Patil Vidyapeeth, Pimpri,
Pune - 411018. India.
Email Id: priyankap044@gmail.com

Priyanka Patil et al., Iontophoresis with Aqueous solution of Nirgundi (*Vitex negundo*, Linn.) in the Management of Pada Kantaka

herbal medicine with the help of Iontophoresis for enhancement of bone healing(10). *Vitex negundo* Linn. (Verbenaceae), locally known as ‘Nirgundi’ is an important medicinal plant. As per Ayurvedic classics *Nirgundi* has *Vata, Kapha, Shoth, Shoola* pacifying properties. Its leaves are widely used externally for rheumatism and inflammations of joints. Aqueous extract of mature fresh leaves exhibit anti-inflammatory, analgesic and antihistamine properties(11). Therefore, Iontophoresis was employed to promote the absorption of aqueous solution of *Nirgundi* through plantar skin in the management of Plantar Fasciitis.

Case report

A 35-year-old female patient, not having history of any medical illness like DM, HTN, a housewife, with a history of long standing daily visited *Shalya tantra* Outpatient Department with the complaint of right heel pain for last 1 year.

Clinical findings

Patient came with preliminary complaint of pain while walking in the morning for first few steps. There was no history any sort of trauma. She consulted a physician and took treatment for 6 months. After that, She was managed with NSAIDs, steroid injections but the relief was for short duration. On general examination, the patient was hemodynamically stable, pulse rate -70/min regular with normal volume and blood pressure – 110/70 mmHg in sitting position. On local examination, range of right ankle joint movement in passive dorsiflexion was within normal limit but pain was there in sole region on passive dorsiflexion. Passive extension of the first metatarsophalangeal joint produced pain along the course of plantar aponeurosis. Severe tenderness elicited at medial aspect of the right heel at the level of calcaneal tuberosity.

Diagnostic focus and assessment

As per the Visual Analogue Score (VAS), the pain was scored as 7 and tenderness was graded as 3 which means severe pain on touch. No bony

abnormality like calcaneal spur or fracture was evident on X-ray of the right foot calcaneal view. Serum uric acid was also within normal limit. Based on these findings, the condition was diagnosed as plantar fasciitis/ *Pada kantaka* and planned to manage by iontophoresis with *Nirgundi* aqueous extract.

Therapeutic focus and assessment

After obtaining written informed consent, the patient was advised for iontophoresis with *Nirgundi* aqueous extract. [Table 1]. Aqueous extract of *Nirgundi* was prepared at Sudhatatva Pharmacy of Dr. D. Y. Patil college of Ayurved And Research centre, Pimpri, Pune after authentication and standardization was done.

No oral medications or other therapies were administrated during the treatment period. Freshly prepared Aqueous extract approx 100 ml was filled in each iontophoresis chamber and the patient was advised to keep his both feet separately in each of the chambers. A weak galvanic current was applied through the iontophoresis machine in anode mode starting from 0.00 mAmp and gradually increased up to 04.0 mAmp. At this point, she felt a maximum tingling sensation in the foot region and current of 04.0 mAmp was allowed to flow for 15 min. Thereafter, 04.0 mAmp current was allowed to flow in the cathode mode for 15 min for the same foot [Figures 1 and 2]. Similar such six sittings on alternate day were given. During the procedure, all metal ornaments were removed and all wires and foot plates were checked. During the course of treatment, she was advised to avoid prolonged weight bearing and use of silicon heel was encouraged.

Follow-up and outcome of the therapy

Significant reduction in the severity of pain was observed after the fourth sitting and the pain was almost relieved by the sixth sitting. The pain on VAS was reduced from 7 to 1 [Graph 1]. No tenderness at medial aspect of the right heel was complained by the patient. After treatment, the patient was followed for three months. No signs and symptoms of plantar fasciitis were reported even after three months of follow-up.

Table 1: Properties of Nirgundi (*Vitex negundo*, Linn.)

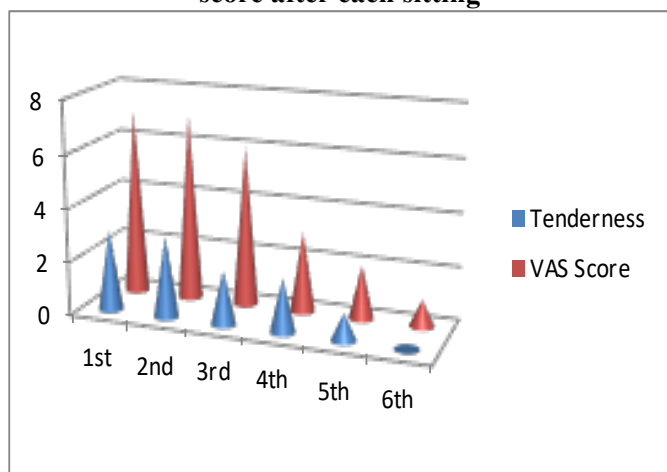
Taste	Characteristics	Potency	Vipak	Function	Properties
Bitter, Pungent	Light , dry	Hot potency	Pungent	Shulahara	Analgesic, Anti inflammatory

Table 2: Timeline

Day	Clinical findings	Intervention
2 March 2020	Severe Pain at right heel for first few steps in the morning since 1 year, tenderness at calcaneal tuberosity, VAS score – 7, tenderness grade 3	First sitting of plantar iontophoresis with Nirgundi aqueous extract for 15 min for each electrode.
4 March 2020	Same as first day	Second sitting of plantar iontophoresis with Nirgundi aqueous extract for 15 min for each electrode
6 March 2020	Pain for first few steps in the morning but mild in severity, VAS score- 5, tenderness grade 2	Third sitting of plantar iontophoresis with Nirgundi aqueous extract for 15 min for each electrode
8 March 2020	Significant relief in pain, VAS score- 3 and tenderness score	Fourth sitting of plantar iontophoresis with Nirgundi aqueous extract for 15 min for each electrode.

10 March 2020	Very negligible discomfort while walking in the morning, VAS score- 2	Fifth sitting of plantar iontophoresis with Nirgundi aqueous extract for 15 min for each electrode.
12 March 2020	Got complete relief in pain and tenderness, VAS score -1	Sixth sitting of plantar iontophoresis with Nirgundi aqueous extract for 15 min for each electrode.

Graph 1 – Improvement in tenderness and VAS score after each sitting



(X axis- sitting Day, Y axis- Gradation of tenderness and VAS on 0th day and 11th day)

Figure 1- Foot plates filled with Nirgundi Aqueous extract and iontophoresis in process



Figure 2- Prepared Aqueous extract of Nirgundi



Discussion

Pada kantik is characterized by pain "just like pricked by thorn (*kantik*)" in the foot (*Pada*) and hence the name "*Pada kantik*". Severe pain (*Rujah*) as a result of localization of the vitiated *vata dosha* in different dushyas. As per the textual references, the features of *Pada kantik* can be accurately paralleled with Plantar fasciitis. Plantar Fasciitis is a degenerative disease of

plantar fascia precipitated by some factors like over stress (long standing, long walking), obesity, walking on hard surface and faulty shoes. Available treatment modalities according to Ayurveda and modern science are mentioned before among that Iontophoresis is also one of the treatment modalities for Plantar Fasciitis. It is a process in which ions in the therapeutic solution are transferred through the intact skin via electrical potential using bipolar electrodes.

Ample references are available regarding the oral as well as topical use of Nirgundi as an analgesic, anti-inflammatory measure without any major side effects. So, Plantar iontophoresis with aqueous solution of Nirgundi has been studied in the management of *Pada kantik*. The active ingredients of *Nirgundi*, permeate through intact skin of the sole and reach the plantar fascia. Plantar fascia being fibrous tissue with limited blood perfusion retains the drug for a relatively longer time. This might explain the anti-inflammatory, analgesic effect of aqueous solution of *Nirgundi*, in an efficient way in plantar fasciitis. Luteolin and apigenin and other active principles present in aqueous solution of *Nirgundi*, prevent cytokine induced cell damage. The COX-2-inhibitory activity of *Nirgundi* may explain in part its anti-inflammatory activity in Plantar Fasciitis. Moreover, flavonoids such as luteolin and apigenin in *Nirgundi* possess anti-inflammatory and anti-arthritis activity(12). flavonoids can penetrate the human skin(13).

This explains mode of action of iontophoresis with *Nirgundi* aqueous extract in the management of *Pada kantik* (Plantar fasciitis).

Conclusion

On the basis of this single case study, it can be concluded that, iontophoresis with aqueous extract of *Nirgundi* is effective in *Pada kantik* as *Nirgundi* has its *Vata, Kapha, Shoth, Shoola* pacifying properties. Its leaves are widely used externally for rheumatism and inflammations of joints. Aqueous extract of mature fresh leaves exhibit anti-inflammatory, analgesic and antihistaminic property.

Iontophoresis might improve absorption of active ingredients of *Nirgundi* like flavonoids which are studied for their antiinflammatory property and which is proven for its human skin penetration. Thus there is a

wide scope for further detail study on number of patients clinically with appropriate data analysis for generalization of the results.

References

1. Mishra, L., Singh, B.B., and Dagenais, S. Ayurveda: A historical perspective and principles of the traditional healthcare system in India, *Altern. Ther. Health Med.*, (2001); 7(2), 36–42.
2. Vaidya Yadavji Trikamji Acharya, *Susrut Samhita with Nibandhasangraha commentary of Dalhan*, Chaukhambha Sanskrit Sansthan, Reprint edition 2009, SutraSthan 33/4-5, Page no. 134
3. Vaidya Yadavji Trikamji Acharya, *Susrut Samhita with Nibandhasangraha commentary of Dalhan*, Chaukhambha Sanskrit Sansthan, Reprint edition 2009, Nidan Sthan 1/79, Page no. 164
4. Ambika dutta Shastri , *Sushruta Samhita*, Edited with *Ayurveda Tattva Sandipika Hindi Commentary* by Kaviraj, Chaukhamba publications, Varanasi, Edition:Reprint 2007, Part 1, Sushruta Sutras than Chapter 12, Shloka 10.
5. Yogratanakar, *Vaidyaprabha Hindi Commentary* Edited by Dr. Indradev Tripathi, 1998, Purvakhand Vatavyadhi Chikitsa, Page no. 524.
6. Vaidya Yadavji Trikamji Acharya, *Susrut Samhita with Nibandhasangraha commentary of Dalhan*, Chaukhambha Sanskrit Sansthan, Reprint edition 2009, Chikitsa Sthan 8/4, Page no. 574
7. *Sushruta Samhita*, Edited with *Ayurveda Tattva Sandipika Hindi Commentary* by Kaviraj Ambika dutta Shastri, Chaukhamba publications, Varanasi, Edition:Reprint 2007, Part 1, Sushruta Chikitsasthan Chapter 4 , Shloka 8.
8. Young CC, Rutherford DS, Niedfeldt MW. Treatment of plantar fasciitis. *Am Fam Physician*. 2001 Feb 1. 63(3):467-74, 477-8.
9. Perelman GK, Figura MA, Sandberg NS: The medial instep Plantarfasciotomy. *J foot Ankle Surgery* 34: 447-457, 1995.
10. Di Yi Jun Yi Da Xue Xue Bao (Academic Journal of the first Medical college of PLA). PMID: 15201098, 2004 Jun;24(6):708-10.
11. Dharmasiri MG, Jayakody JRAC, Galhena G, Liyanage SSP, and Ratnasooriya WD. 2003. Anti-inflammatory and analgesic activities of mature fresh leaves of *Vitex J negundo*. *Journal of Ethnopharmacology* 87(23):199 2003 August ; 87(2-3): 199-206; doi 10.1016/s0378-8741(03) 00159-4
12. Bansod and Harle, *Vitex Negundo: Phytochemical constituents, traditional use and Pharmacological properties: Comprehensive review*; *Pharmacologyonline* 1:286-302(2009) Newsletter, Page no.- 286-302
13. Seelinger G, Merfort I, Wolfle U, Schempp CM.; Anticancerogenic effects of the Flavonoid Leutiolin. *Molecules*. 2008 Oct 22;13(10):2628-51. Doi:10.3390/molecules13102628 PMID:18946424; PMCID:PMC6245397.
